# The role of dual imaging modalities PET/CT and SPECT/CT in thyroid cancer patients

**I. Igerc, Klagenfurt (AT)**

Differentiated (papillary and follicular) thyroid cancer (DTC) is a tumor with a generally good prognosis representing a long-term survival in low-risk groups of 99%. However in intermediate- and high-risk groups recurrence is not uncommon with a long term survival in intermediate- and high-risk patients of 87%, and 57%, respectively (1). The standard management of thyroid cancer patients is the (near) total thyroidectomy, followed by a high dose radioiodine therapy after 4-6 weeks, suggesting that remnant ablation may reduce the risk of recurrence, development of metastases, and long-term mortality from differentiated thyroid cancer. Posttherapeutic whole body scintigraphy after iodine-131 therapy in thyroid cancer patients is of great importance regarding effectiveness of therapy and staging. Precisely anatomical localisation of foci with increased uptake and the determination of physiologically or pathologically iodine-131 uptake is sometimes difficult on planar images. Software image fusion was introduced several years ago, and proved helpful for anatomic localisation of abnormalities detected on SPECT imaging (2). However, while very useful, this technique involves fusion of images acquired during two separate imaging sessions on two different scanners with the possibility of misregistration and at the cost of scanner, patient, and technologist time. SPECT/CT is similar conceptually to PET/CT. The SPECT and CT are acquired sequentially during a single imaging session. The CT information is used for attenuation correction and anatomic localisation. SPECT/ CT is performed on a single device during a single imaging session, which permits higher precision coregistration of the images. In some cases, however, it has a further clinical impact on the patients' management. In the case of inconclusive findings in conventional planar posttherapeutic whole body scintigraphy, SPECT-CT can be performed of the region of interest (neck, thorax, abdomen or extremities). Especially in patients after the first ablative therapy precisely anatomic localisation can be a challenge and SPECT/CT is helpful for differentiating thyroid remnant from a lymph node metastasis. (Fig.1).

Also in the remaining whole body, i.e. the thoracical and abdominal region SPECT/CT may be of great importance for accurately localizing an inconclusive finding and may upstage the M status or change the M status (Fig.2). Furthermore iodine-131 negative metastases can also be found on SPECT/CT images.

However, iodine-131 scans have been found to have a sensitivity of only 50–69% for the detection of thyroid malignancies (3). The approximately 40% of lesions without any iodine-131 uptake seem to be metastases with dedifferentiation, which worsen the prognosis and have to be detected early by other imaging modalities. Progressive dedifferentiation of thyroid cancer cells leads to a loss of iodine-concentrating ability and these poorly differentiated thyroid cancer lesions present a relatively high glucose consumption rate. This alternating pattern of metastases with either iodine-131 or FDG-uptake is called flip-flop phenomenon (Fig. 3). Because of its relative sensitivity, FDG-PET has become a well-established method in the follow-up of DTC patients with elevated thyroglobulin (Tg) and negative iodine-131 scans. Depending on the Tg level, its sensitivity may reach 94% and its specificity 90%, in the detection of DTC metastases or local recurrences (4). At the 3rd German interdisciplinary consensus conference, FDG-PET was graded as a 1a indication ("established clinical use") in restaging radioiodine-negative lesions and as a 1b indication ("clinical use probable") in radioiodine-positive lesions if additional local recurrence or metastases are suspected on the basis of elevated Tg levels (5). FDG-PET gives functional and metabolic information and CT gives morphological information Fusion of both imaging modalities gives additional information in more than 50% of patients. Elevated thyroid stimulating hormone levels have a positive effect on the uptake of FDG in DTC recurrences or metastases and have been recommended for FDG-PET examinations. Visualising the pathological glucose metabolism in the context of the detailed anatomical structure in one setting assists in planning surgical treatment or radiation therapy. PET/CT should be preferred to PET in the follow-up of DTC patients with iodine-131 negative whole-body scans and elevated Tg levels. FDG-PET/CT markedly improves upon the diagnostic value of FDG-PET in such cases, can result in the modification of treatment plans and may reveal unexpected pathological findings. It integrates the strengths of CT in visualising lung metastases and detailed morphological changes and of PET in detecting vital tumor tissue, especially in lymph nodes, local recurrence and bone.

**References**

1. Shaha AR. Implications of prognostic factors and risk groups in the management of differentiated thyroid cancer. Laryngoscope 2004;114:393-402.
2. Yamamoto Y, Nishiyama Y, Monden T, Matsumura Y, Satoh K, Ohkawa M. Clinical usefulness of fusion of 131I SPECT and CT images in patients with differentiated thyroid carcinoma. J Nucl Med 2003;44(12):1905-10.
3. Iwata M, Kasagi K, Misaki T, Matsumoto K, Iida Y, Ishimori T, et al. Comparison of whole-body 18F-FDG PET, 99mTc-MIBI SPECT, and post-therapeutic 131I-Na scintigraphy in the detection of metastatic thyroid cancer. Eur J Nucl Med Mol Imaging 2004;31:491–8.
4. Helal OB, Merlet P, Toubert ME, Franc B, Schvartz C, Gauthier-Koelesnikov H, et al. Clinical impact of 18F-FDG PET in thyroid carcinoma patients with elevated thyroglobulin levels and negative 131I scanning results after therapy. J Nucl Med 2001;42:1464–9.
5. Reske SN, Kotzerke J. FDG-PET for clinical use: results of the 3rd German interdisciplinary consensus conference, "Onko-PET III", 21 July and 19 September 2000. Eur J Nucl Med 2001;28:1707–13.

*Figure 1*

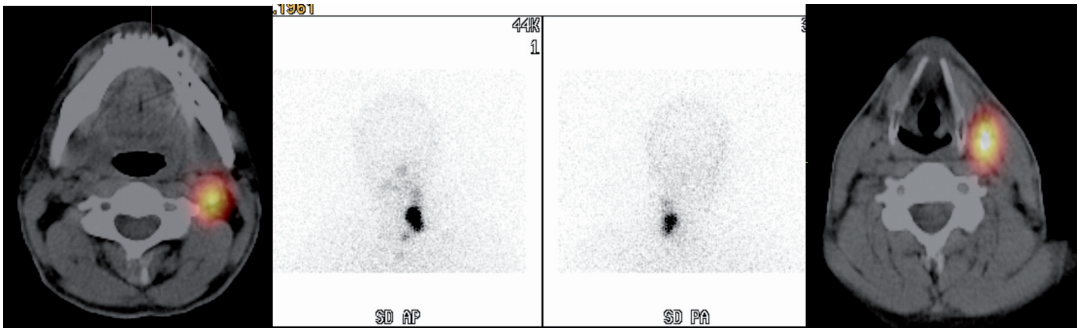


Iodine-131 positiv lymphnode metastases in the cervical region on the left side, additional surgery was performed offering the surgeons preoperatively a prezise anatomical information.

*Figure 2*

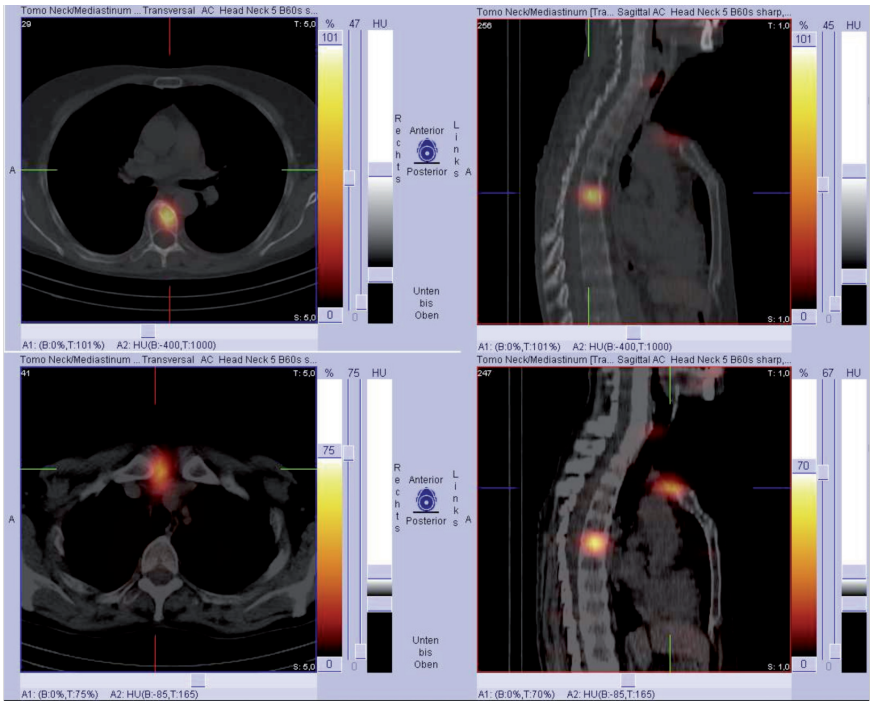


SPECT/CT images of a patient with iodine-131 positive metastases indicating a bone metastasis in the thoracic spine and a supraclavicular lymphnode metastasis on the right side.

*Figure 3a*

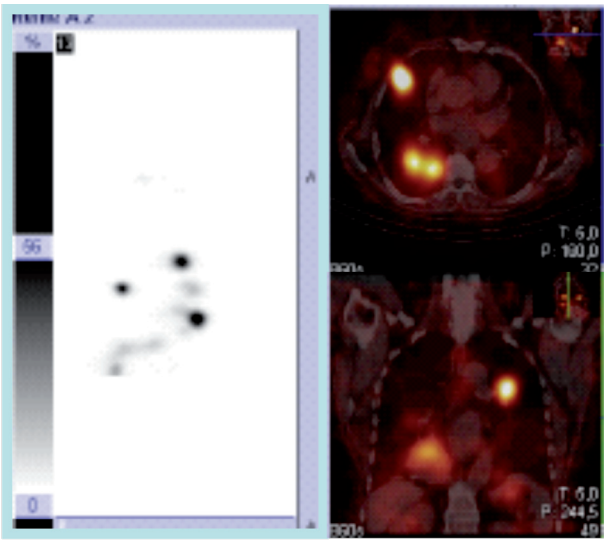

SPECT/CT after therapy indicating iodine-131 positive lung metastases.

*Figure 3b*

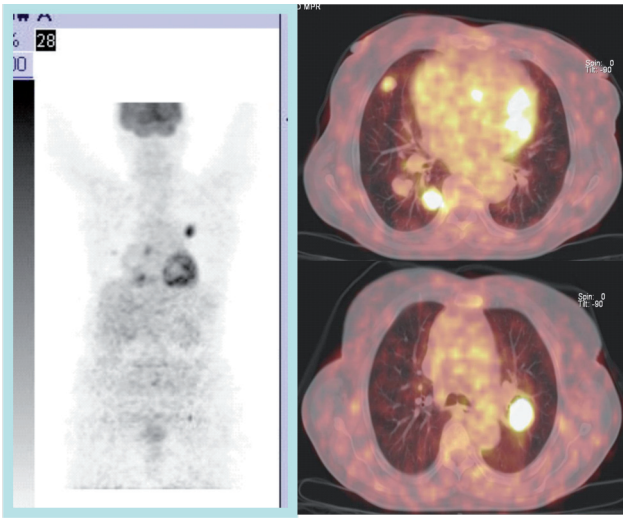

FDG-PET/CT images of the same patient with highly elevated FDG uptake in some of the lung metastases.