Solitary thyroid nodules – differential diagnosis

D. Huic, Zagreb (HR)

Thyroid nodules are common, with 4% -7% of the adult population having palpable nodules. Widespread use of ultrasound increased this number to 19%-67%. In autopsy they have a prevalence of approximately 50%. The appearance of thyroid nodules increases with age and women have a higher prevalence than men. Majority of the nodules are benign, and about 5% are malignant. The primary goal in investigating thyroid nodules is to identify the nodules with malignant potentials.

In the diagnostic work-up several diagnostics tests are available. The choice of the test depends on the local experience, but in most institutions ultrasound examination is the first in the line. By using ultrasound we are able to get information about the site, size, echo structure and vascularisation of the thyroid node, and additionally, local lymph node status of the neck. Findings suggestive of differentiated thyroid cancer are hypoechogenic structure, irregular and ill-defined margins, absence of halo sign, microcalcifications and intranodular vascularisation. Hypoechogenic nodules are very sensitive for cancer (more than 90%), but this sign has very low specificity (5-10%) because more than 70% of thyroid adenomas are hypoechogenic. A few findings suggestive of differentiated thyroid cancer (absence of halo sign, microcalficications, marked intraglandular blood flow) are very specific (97.2%) but also insensitive (16.6%), because this combination is found only in minority of thyroid cancers.

By using scintigraphy (performed with Tc-99m pertechnetate or I-123) we are able to virtually exclude thyroid cancer in "hot" nodules (probability less than 4%). Uptake of those isotopes depends on the density and activity of sodium / iodine symporter (NIS) which is protein located on the basolateral membrane of the follicular cells.

If the nodules appear "cold" the chance for malignancy is about 10%-25% with specificity of only 10%, because decrease or loss of NIS activity is found in most thyroid carcinomas, as well as adenomas. Additional limitation of scintigraphy is limited spatial resolution (threshold about 1cm) with best visualization of lesions located anteriorly in non-enlarged glands.

Most accurate single test for the estimation of thyroid nodules is fine-needle-aspiration (FNA). It is generally well tolerated, with minor complications of local pain and, very rarely, a hematoma. Sensitivity of FNA in palpable nodules without "hot" nodules on scan is 91.8%, with specificity of 75%. Pre-test probability of thyroid cancer of 4% can be reduced to 0.4% with benign cytology, but with positive citology probability for cancer increases to 90.7%. Nondiagnostic cytology (10%-20%) is attributed to the group of smears when there are insufficient follicular cells to make a cytological diagnosis. Repeated aspiration yields satisfactory smears in 50% of cases. There is also problem for lesions suggestive of follicular tumor when it is not possible to discriminate between follicular adenoma and carcinoma, which can only be determined on histology.

In addition to above mentioned methods some biochemical evaluation of thyroid nodules should be performed. In fact, assessment of the nodules should begin with assessment of the functional status of the thyroid by measuring thyroid-stimulating hormone (TSH) as a most useful initial step. The other markers which can be helpful elucidating thyroid function are thyroid hormones, thyroid antibodies, thyroglobulin and calcitonin.

Simple way to manage thyroid nodules is shown in the graph.

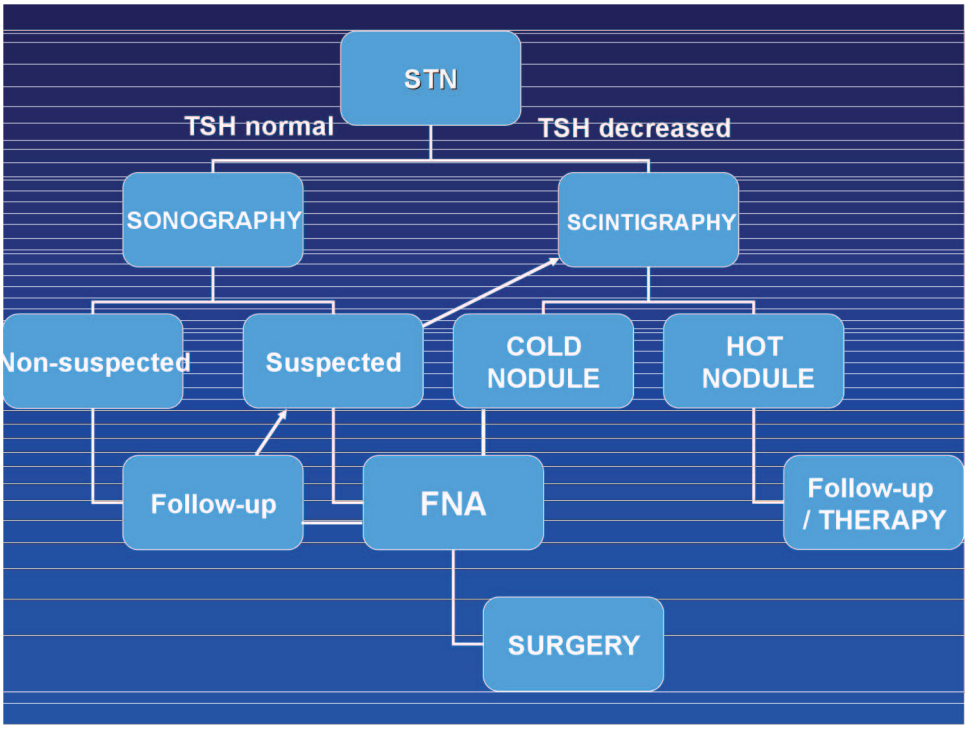

References

1. L. Clinical practice. The thyroid nodule. N Engl J Med 2004;351:1764-1771.
2. Mitchell J, Parangi S. the thyroid incidentaloma: An increasingly frequent consequence of radiologic imaging. Semin Ultrasound CT MR 2005;26:37-46.
3. Yeung MJ, Serpell JW. Management of the solitary thyroid nodule. The Oncologist 2008;13:105-112.
4. Ogilvie JB, Piatigorsky EJ, Clark OH. Current status of fine-needle aspiration for thyroid nodules. Adv Surg 2006;40:223-238.
5. Wong CK, Wheeler MH. Thyroid nodules: Rational management. World J Surg 2000;24:934-941.